



ON FIELD MANAGEMENT OF PATELLA DISLOCATION

J. Kristopher Ware MD, DPT

Orthopedic Associates of Hartford

Bone and Joint Institute/ Hartford Hospital



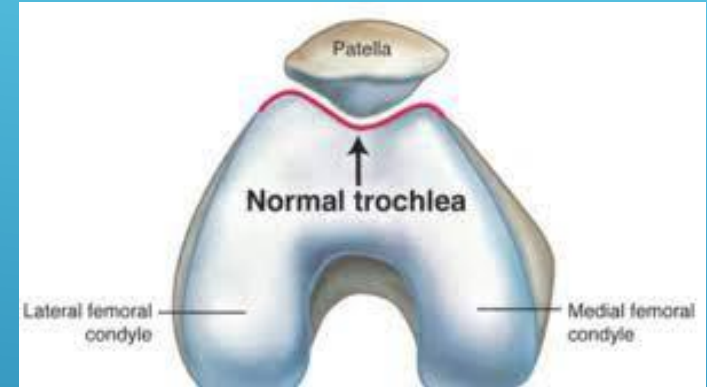
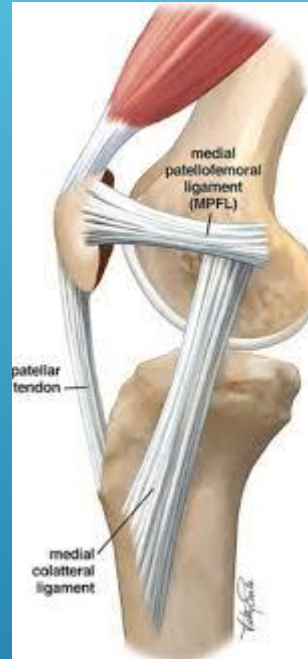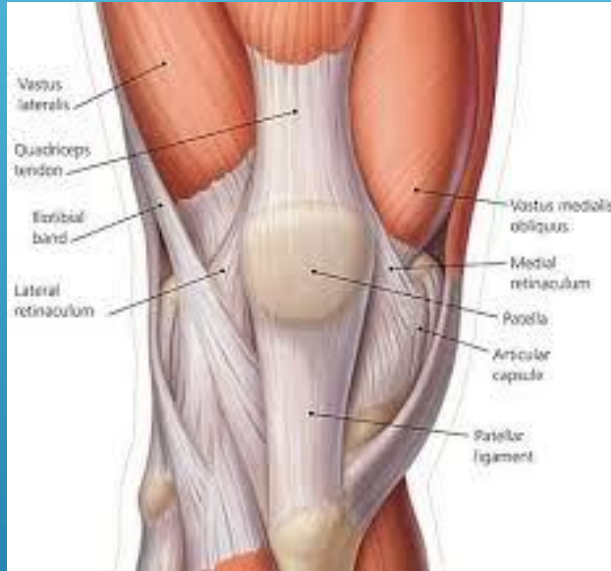- ▶ I have no financial interest or contractual relationships with any commercial interest relating to this presentation.
- ▶ The views expressed in these slides and today's discussion are my own.

DISCLOSURES



- ▶ Recognize signs of patella dislocation
- ▶ Discuss acute evaluation for patellar dislocations
- ▶ Review reduction technique for patellar dislocations

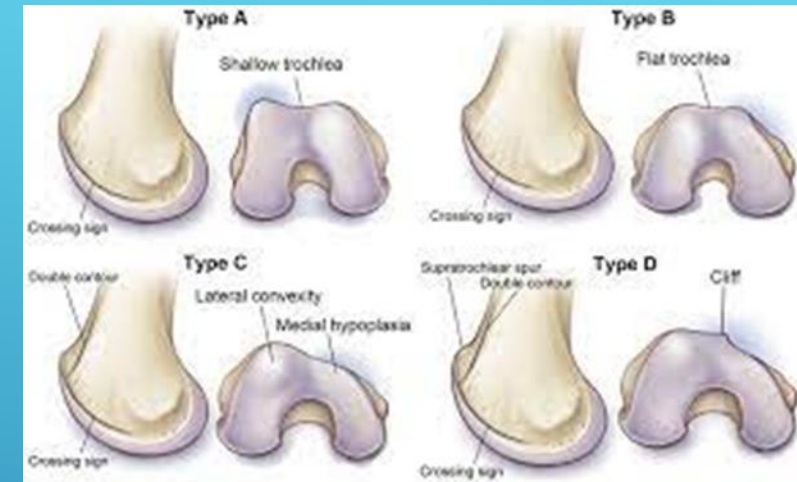
OBJECTIVES



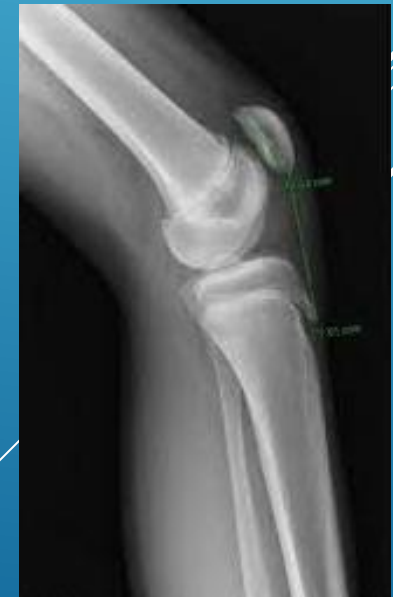KNEE ANATOMY



- ▶ Age <20
- ▶ Generalized hypermobility
- ▶ Trochlear dysplasia
- ▶ Patella alta
- ▶ Lower extremity malalignment
 - ▶ Genu valgum with femoral anteversion

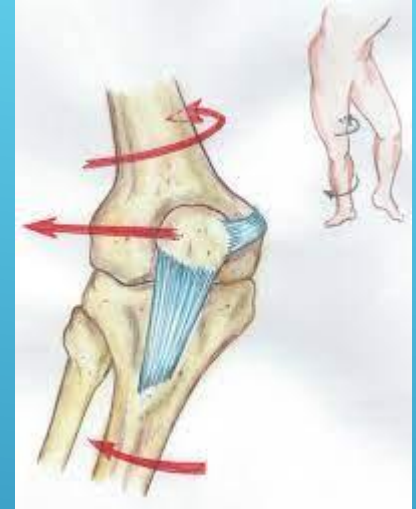


RISK FACTORS FOR PATELLAR DISLOCATION





- ▶ Almost always Lateral patellar dislocation
- ▶ Most common: non contact, Knee flexion with valgus/ external rotation
- ▶ Direct impact: knee to knee/ helmet to knee

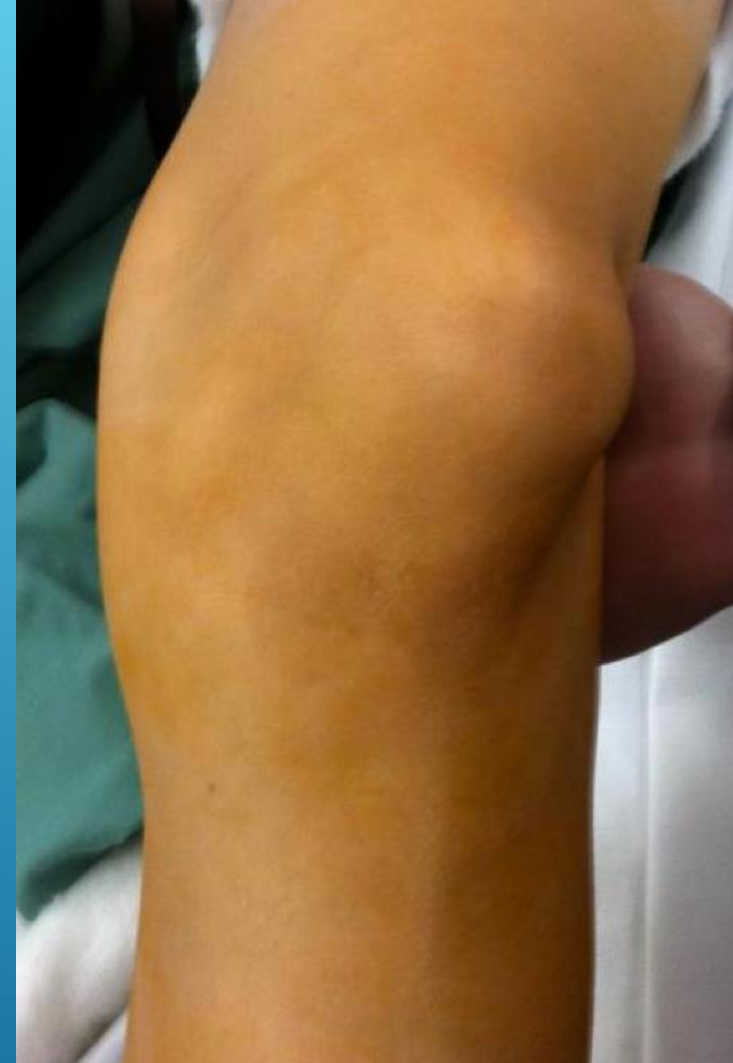

MECHANISM OF INJURY



- ▶ Visible deformity
- ▶ Knee held flexed
- ▶ Large hemarthrosis
- ▶ Tender over medial patella and MFC

PRESENTATION





- ▶ First perform neurovascular screen
- ▶ Check tibiofemoral stability
- ▶ Palpate for crepitus
- ▶ Reduction:
 - ▶ Gently extend knee while providing gentle manipulation of the patella

REDUCTION



- ▶ Neurovascular screen
- ▶ Check straight leg raise
- ▶ Ligamentous exam
- ▶ Immobilize in extension
- ▶ Early follow up with xrays to rule out fracture/ loose bodies

POST REDUCTION



- ▶ Duthon VB. Acute traumatic patellar dislocation. *Orthop Traumatol Surg Res.* 2015 Feb;101(1 Suppl):S59-67. doi: 10.1016/j.otsr.2014.12.001. Epub 2015 Jan 12. PMID: 25592052.
- ▶ Johnson DS, Turner PG. Management of the first-time lateral patellar dislocation. *Knee.* 2019 Dec;26(6):1161-1165. doi: 10.1016/j.knee.2019.10.015. Epub 2019 Nov 11. PMID: 31727430.
- ▶ Panni AS, Vasso M, Cerciello S. Acute patellar dislocation. What to do? *Knee Surg Sports Traumatol Arthrosc.* 2013 Feb;21(2):275-8. doi: 10.1007/s00167-012-2347-1. Epub 2012 Dec 15. PMID: 23242381.
- ▶ Parikh SN, Veerkamp M, Redler LH, Schlechter J, Williams BA, Yaniv M, Friel N, Perea SH, Shannon SR, Green DW. Patellar Instability in Young Athletes. *Clin Sports Med.* 2022 Oct;41(4):627-651. doi: 10.1016/j.csm.2022.05.005. PMID: 36210163.
- ▶ Tsai CH, Hsu CJ, Hung CH, Hsu HC. Primary traumatic patellar dislocation. *J Orthop Surg Res.* 2012 Jun 6;7:21. doi: 10.1186/1749-799X-7-21. PMID: 22672660; PMCID: PMC3511801.

REFERENCES



THANK YOU!