



An Interactive Learning Experience: Revalidation of Clinical Skills for AT Professionals & AT Educators

Skin Pathology Assessment

Jeffrey R. Brown, MD

Director of Primary Care Sports Medicine, CT Sports Medicine Institute
St . Francis Hospital - Trinity Health Of New England
Asst. Fellowship Dir. , UCONN Primary Care Sports Medicine Fellowship
Team Physician, Central CT State University

1

Disclosure Slide

- No conflicts of interest
- No relevant financial relationships



2

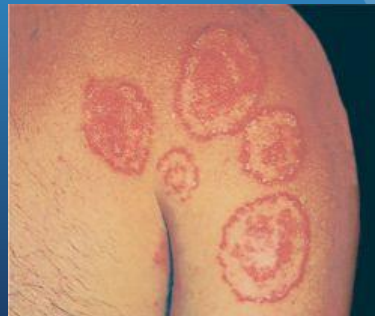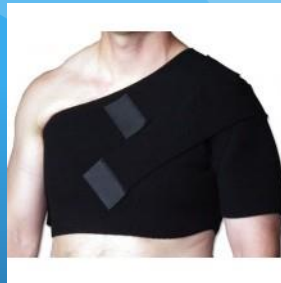Learning Objectives

- At the end of the session, the participant will be able to:
 - Identify and differentiate between common skin conditions, such as infections, inflammatory disorders, and potentially serious lesions
 - Demonstrate proficiency in performing a systematic skin assessment, including inspection and palpation techniques, and accurately document findings using appropriate medical terminology
 - Develop the ability to assess whether a skin lesion requires immediate intervention, ongoing monitoring, or referral to a specialist, while considering the implications for athlete participation and infection control

3

Case - What is it?

- 17 yo basketball player with left anter. shoulder instability
- Sully brace
- 3 days of “rash”
- “a little itch”
- “slowly increasing in size”
- “What is it?”



4

Dermatology Terminology

- Accurate Description
 - → Quick Diagnosis
 - → Expedited treatment
 - → Faster Resolution of Sx
 - → Return-to-Play

5

Describing a Skin lesion: Dermatology Terminology

- Location/Distribution
- Type of Lesion - macule, papule, patch, plaque, pustule, nodule, vesicle, wheal, cyst
- Color
- Size
- Shape - round, oval, annular (ring shaped)
 - Marginated - well or ill-defined

6

Dermatology Terminology

- Arrangement of multiple lesions
 - Grouped
 - Disseminated
- Palpation
 - Consistency
 - Temperature
 - Tenderness
 - Mobility
 - Depth

7

Dermatology Terminology: Secondary Lesions - Result of Primary lesion

- **Scale** - flakes of skin
 - Ex: psoriasis
- **Crust** - dried bacteria, cells, fluid on the skin
 - Ex: impetigo
- **Fissure** - crack in skin
 - Ex: chapped lips
- **Ulcer** - loss of epidermis and some dermis
 - Ex: pressure sore
- **Scar** - healed dermis after injury
 - Ex: burn, cut, etc. after healing
- **Excoriation** - abraded epidermis and dermis from scratching
 - Ex: scratches
- **Pigment changes** - increase or decrease in melanin
 - Ex: vitiligo

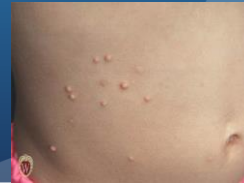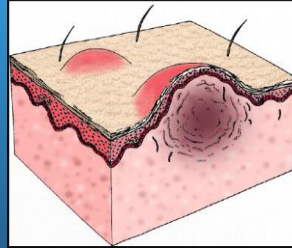
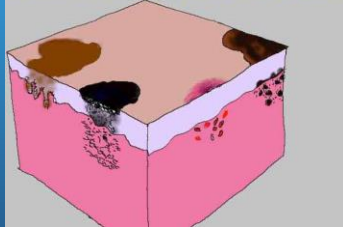
8

Dermatology Terminology: Type of Lesion

Macule -- flat, discolored
area <1-2cm - Ex: freckle

Papule - solid, elevated
lesion up to 1cm - Ex: wart

Macules are flat. They cannot be palpated.

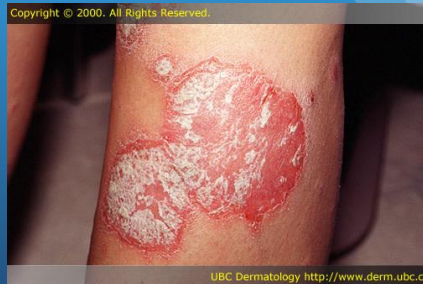
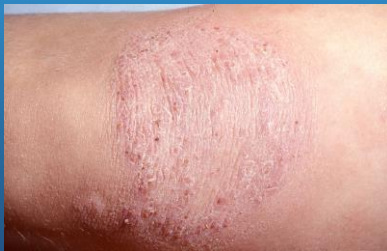
9

Dermatology Terminology: Type of Lesion

Patch - large macule >2cm
Ex: nummular eczema

Plaque - flatly elevated
>1cm; Ex: psoriasis



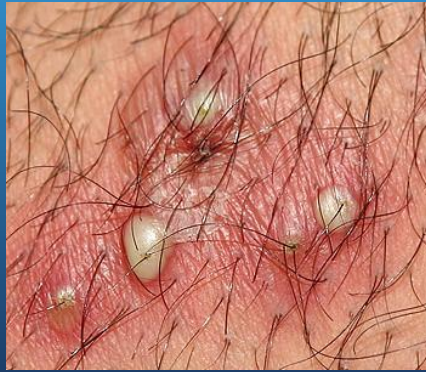UBC Dermatology <http://www.derm.ubc.ca>

10

Dermatology Terminology: Type of Lesion

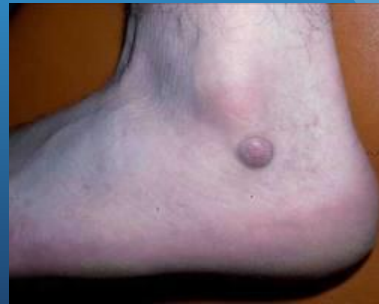Pustule - circumscribed
elevated lesion w/pus.

Ex - folliculitis



Nodule - palpable, solid
lesion >0.5cm, but <2cm.

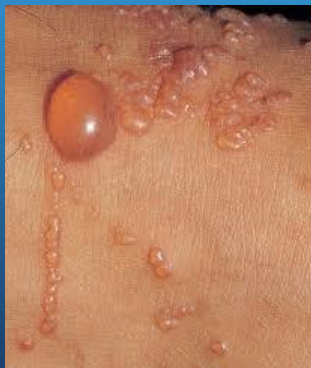Ex - Dermatofibroma



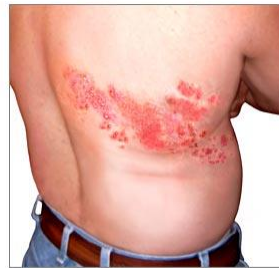11

Dermatology Terminology: Type of Lesion

Vesicle - circumscribed,
elevated lesion w/free fluid
Ex - poison ivy (cont derm)



Ex - Shingles - Varicella-
Zoster-Virus



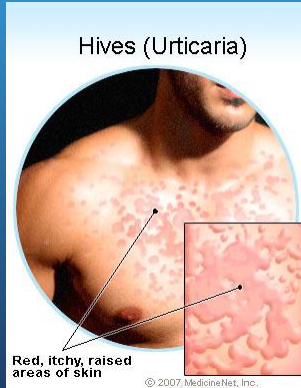
Shingles

ADAM.

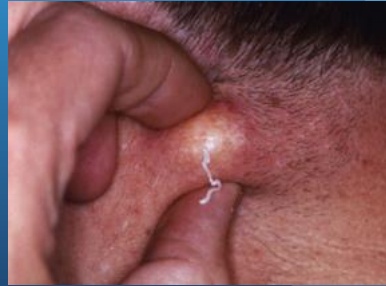12

Dermatology Terminology: Type of Lesion

Wheal - rounded, elevated lesion formed by local dermal edema. Ex - Hives



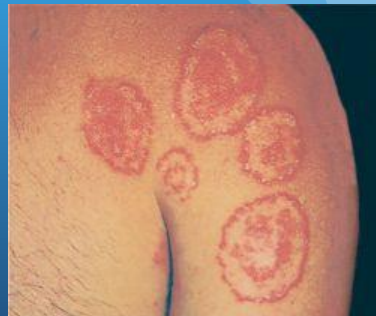Cyst - sac containing liquid or semisolid material in dermis. Ex - sebaceous cyst



13

Back to Case - Tinea Corporis

- “on the athlete’s left arm, there are five ringed, erythematous lesions in a group, measuring 2-4 cm in diameter. All have a raised border and central clearing”



14

References

- Ely, J, Rosenfeld S, Stone, MS. Diagnosis and Treatment of Tinea Infections. *American Family Physician*. 2014; 90 (10): 702-711.
- Frazier, WT, Proddatur, S, Swope, K. Common Dermatologic Conditions in Skin of Color. *American Family Physician*. 2023; 107 (1): 26-34.
- Liebich C, Wegin V, Marquart C, et al. Skin Diseases in Elite Athletes. *Int J Sports Med*. 2021; 42(14):1299-1304.
- Pujalte GGA, Costa LMC, Clapp AD, et al. More Than Skin Deep: Dermatologic Conditions in Athletes. *Sports Health*. 2023; 15(1): 74-85.
- Shen-Wagner, J, Amidon J, Carek, S. Diagnosing Benign Skin Tumors. *American Family Physician*. 2024; 110 (4): 353-361.