

Trinity Health

Connecticut Musculoskeletal Cancer Alliance

## Lumps & Bumps

--When to be concerned--

Eric Silverstein, MD  
Director of Musculoskeletal Oncology  
Academic Director of Orthopaedic Surgery  
Saint Francis Hospital & Cancer Center  
Trinity Health of New England

33<sup>rd</sup> Sports Medicine Symposium  
March 6, 2018

Trinity Health Of New England

Connecticut Joint Replacement Institute

---

---

---

---

---

---

---

---

## Disclosure

- I have nothing to disclose and have no potential conflict of interest with any company or service industry

Trinity Health Of New England

---

---

---

---

---

---

---

---

## Objectives

- Identify the "red flags" of musculoskeletal lesions
- Case examples of tumors that may emulate sports pathology
- Understand the basics of musculoskeletal oncologic staging
- Provide an introduction to the pitfalls of poorly planned and performed biopsies
- Know when to refer a patient with musculoskeletal lesions

Trinity Health Of New England

---

---

---


---

---

---


---

---



## Musculoskeletal Oncology

- Division of orthopaedics focusing on surgical treatment of soft-tissue and bone tumors (and simulators)
- Requires multi-disciplinary approach
- Often extensive radiologic imaging
- Staging / Carefully planned biopsies
- Vast array of surgical intervention and reconstruction



---

---

---


---

---

---


---

---



## Case #1

- 30 year old male
- Chief complaint: Mass in left thigh
- HPI: Healthy male with slowly enlarging mass in anterior thigh over 6 months. Causing minimal to mild discomfort.
- ROS: negative
- X-RAYS: negative



---

---

---


---

---

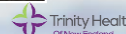
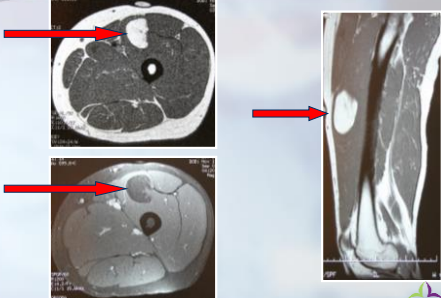
---

---

---



## Case #1



---

---

---

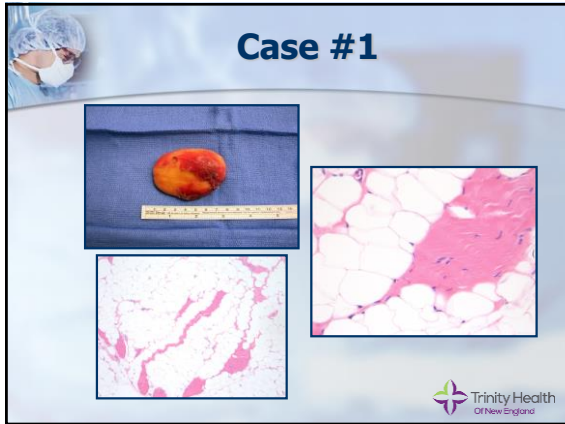
---

---

---

---

---



---

---

---

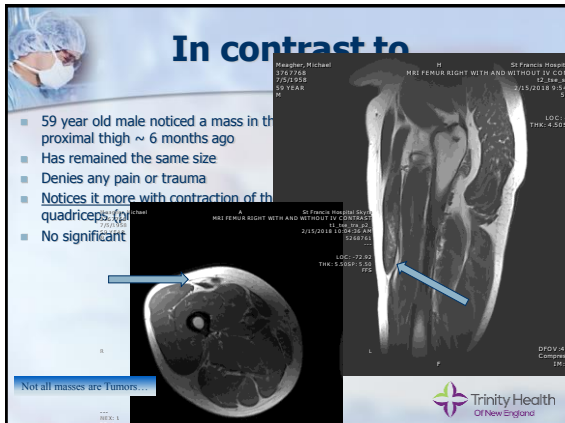---

---

---

---

---



---

---

---

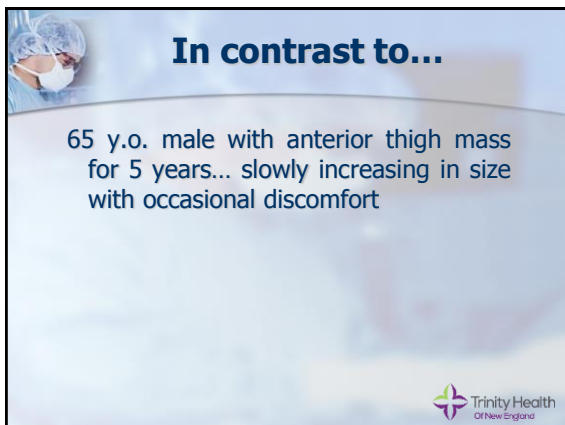
---

---

---

---

---



---

---

---

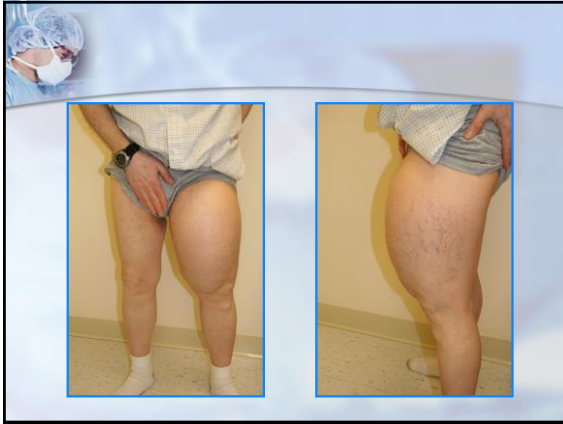---

---

---

---

---



---

---

---

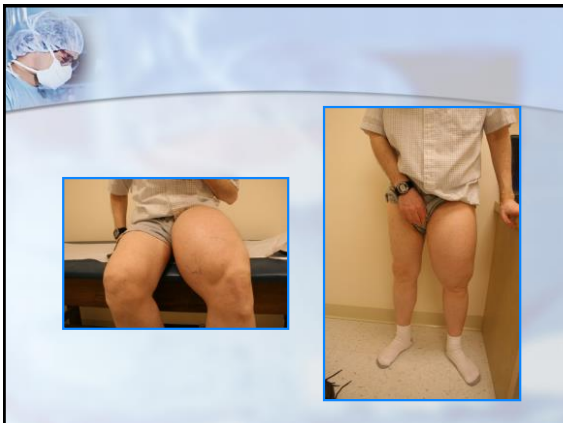---

---

---

---

---



---

---

---

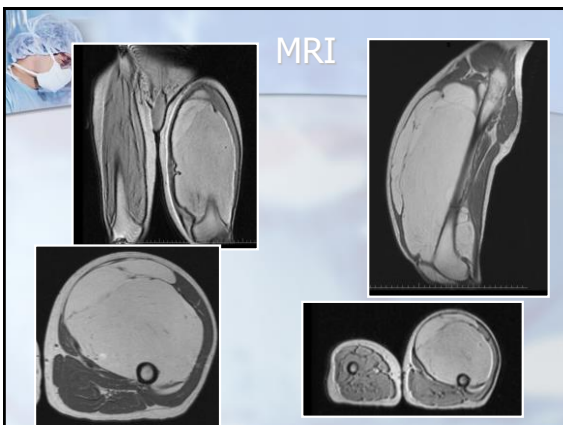
---

---

---

---

---



---

---

---

---

---

---


---

---

### Case #2

10 y.o. female

- Chief complaint: Left knee pain
- Healthy with no PMHx
- Was sailing and struck Left leg against the boat during turbulence
- Had pain but able to walk
- **Pain persisted** despite conservative management for the next 4-6 weeks



---

---

---

---


---

---

---

---

### Case #2



---

---

---

---

---


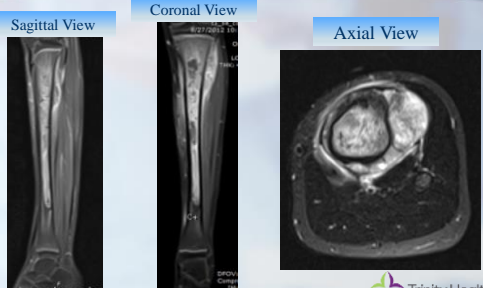
---

---

---

### Case #2

Sagittal View      Coronal View      Axial View



---

---

---

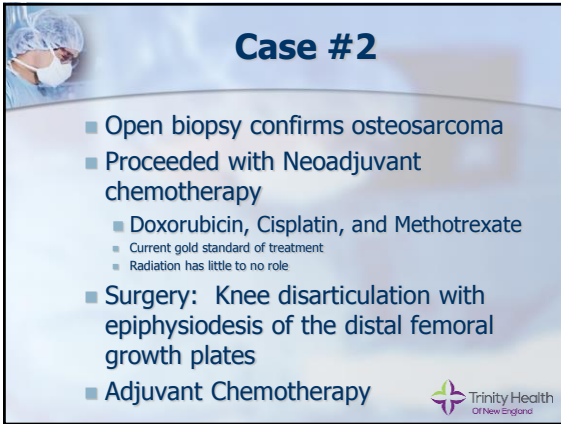
---

---

---


---

---



**Case #2**

- Open biopsy confirms osteosarcoma
- Proceeded with Neoadjuvant chemotherapy
  - Doxorubicin, Cisplatin, and Methotrexate
    - Current gold standard of treatment
    - Radiation has little to no role
- Surgery: Knee disarticulation with epiphysiodesis of the distal femoral growth plates
- Adjuvant Chemotherapy



---

---

---

---

---

---

---

---



**Case #2**



---

---

---

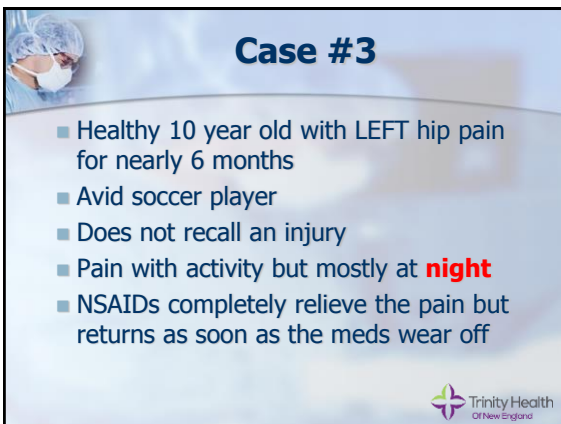
---

---

---


---

---



**Case #3**

- Healthy 10 year old with LEFT hip pain for nearly 6 months
- Avid soccer player
- Does not recall an injury
- Pain with activity but mostly at **night**
- NSAIDs completely relieve the pain but returns as soon as the meds wear off



---

---

---

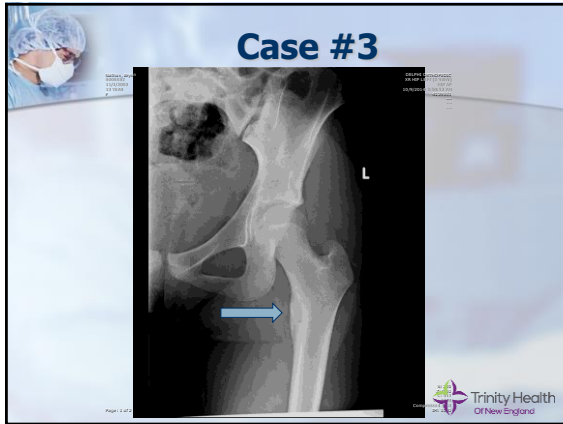
---

---

---

---

---




---

---

---

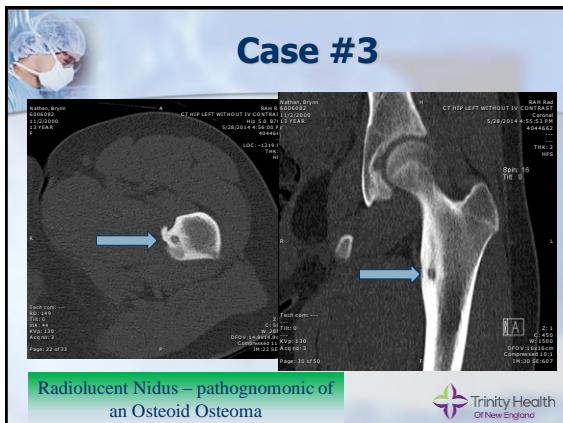
---

---

---

---

---




---

---

---

---

---

---

---

---

**Case #3**

- Conservative management with daily NSAIDs
  - Although osteoid osteomas are self limiting they often persist on average 3-5 years before "burning out"
  - Prolonged use of NSAIDs – ulcers\*, kidney damage, etc.
- Surgery
  - Radiofrequency ablation
  - Open excision
  - Other modalities (?)

Trinity Health  
Of New England

---

---

---

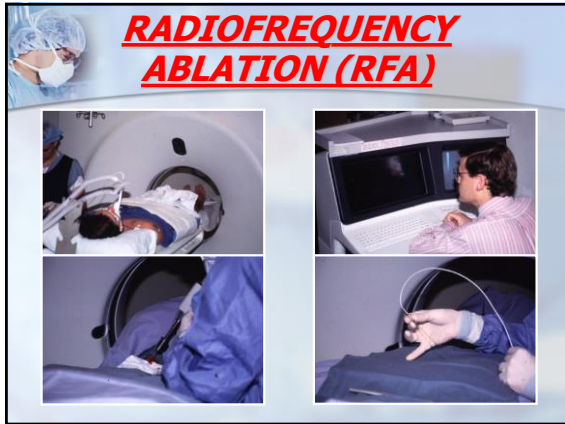---

---

---

---

---



---

---

---

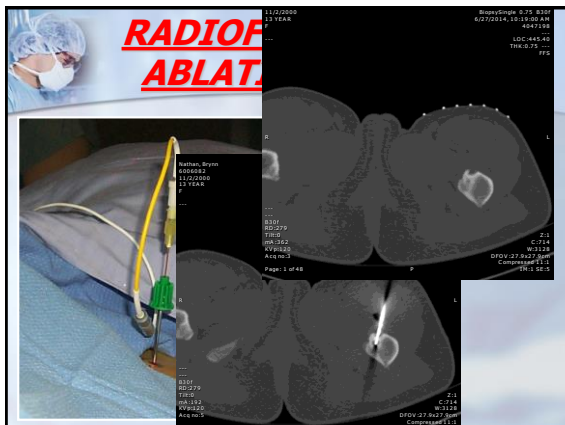
---

---

---

---

---



---

---

---

---

---

---

---

---

### Case #4

37 y.o. female

- Chief complaint: Shoulder pain w/ mass and swelling
- 30 weeks pregnant
- Symptoms present for nearly 7 months
- Otherwise healthy
- Went to see sports doc

Trinity Health  
of New England

---

---

---

---

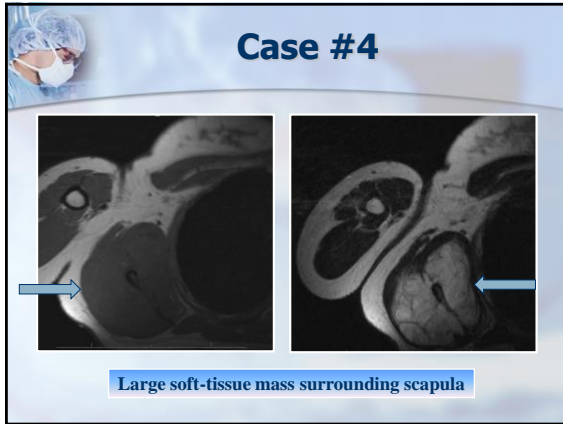
---

---

---

---





---

---

---

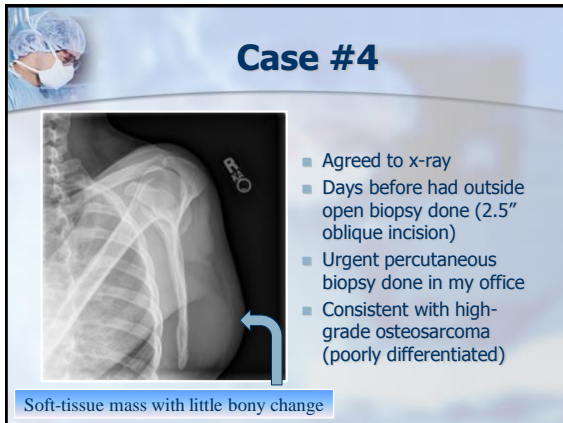
---

---

---

---

---



---

---

---

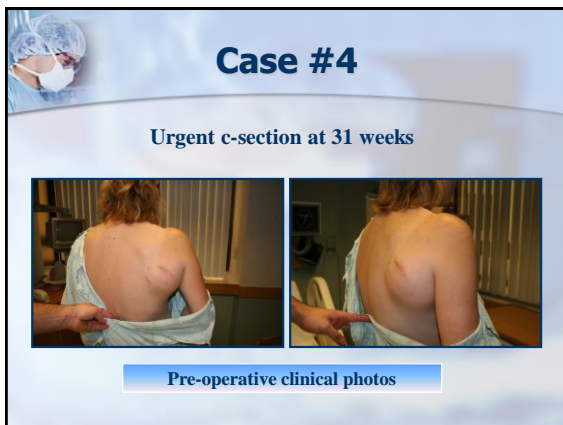---

---

---

---

---



---

---

---

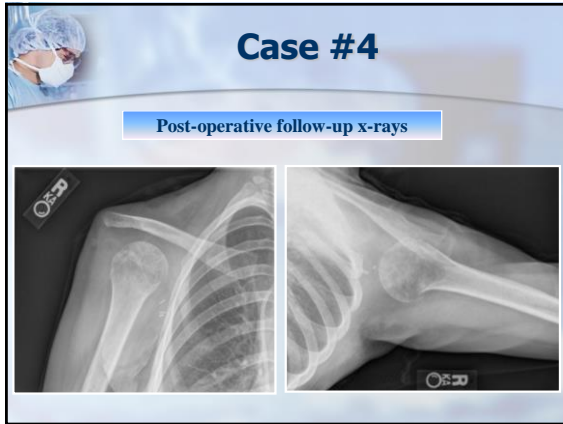
---

---

---

---

---



---

---

---

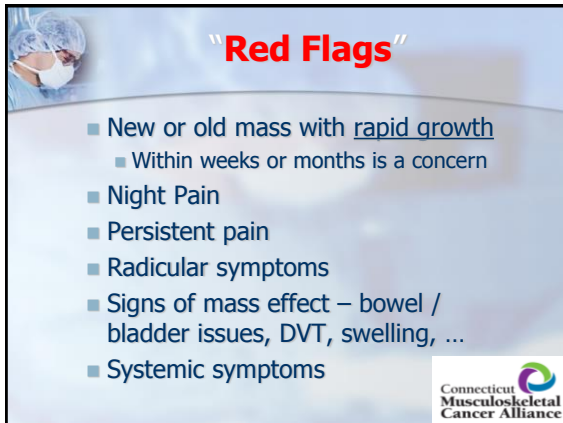---

---

---

---

---



---

---

---

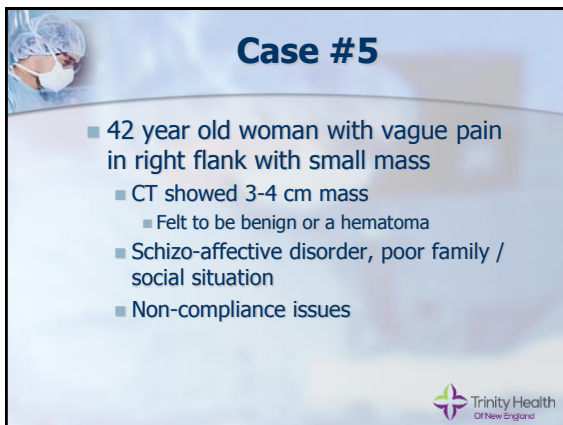
---

---

---

---

---



---

---

---

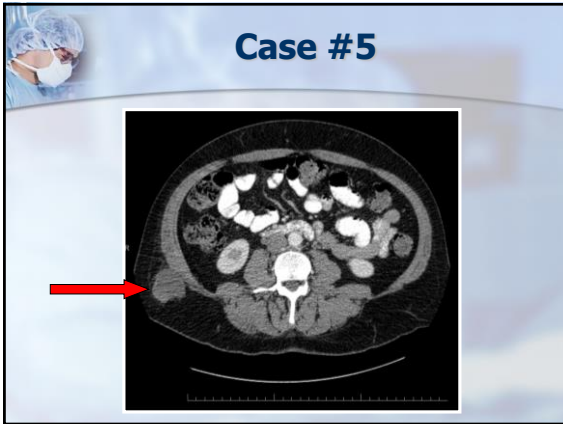
---

---

---

---

---



---

---

---

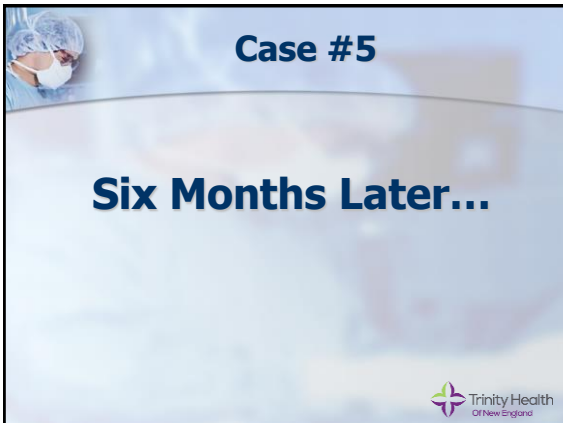---

---

---

---

---



---

---

---

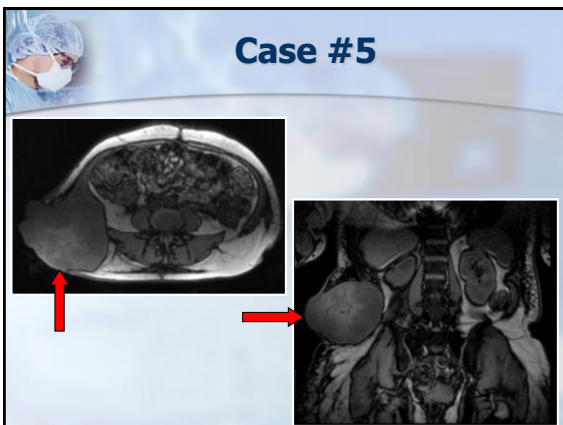
---

---

---

---

---



---

---

---

---

---


---

---

---

**Case #6**

- 15 year old female
- High school student and volleyball player
- Long history of bilateral patello-femoral symptoms
- Otherwise healthy
- X-ray showed abnormality and sent for evaluation



---

---

---

---

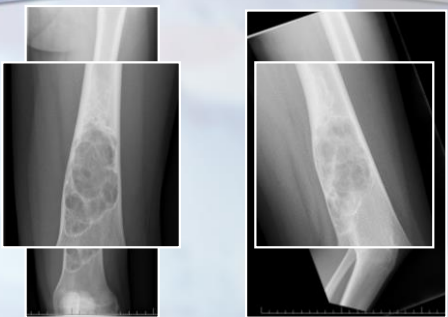
---

---

---

---

**Case #6**



---

---

---

---

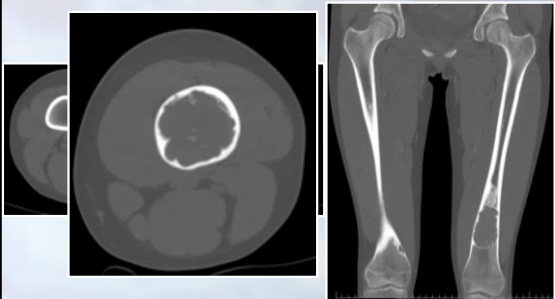
---

---

---

---

**Case #6**



---

---

---

---

---

---

---

---



---

---

---

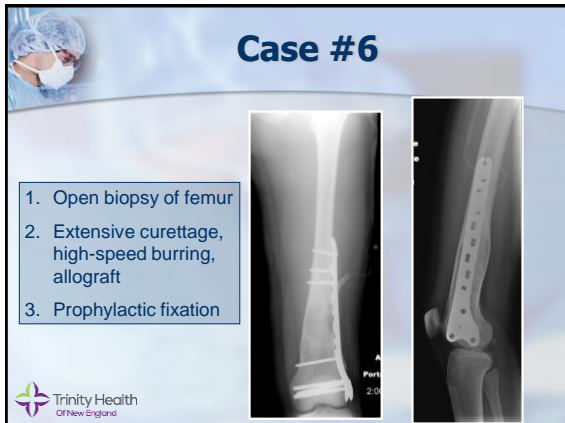
---

---

---

---

---



---

---

---

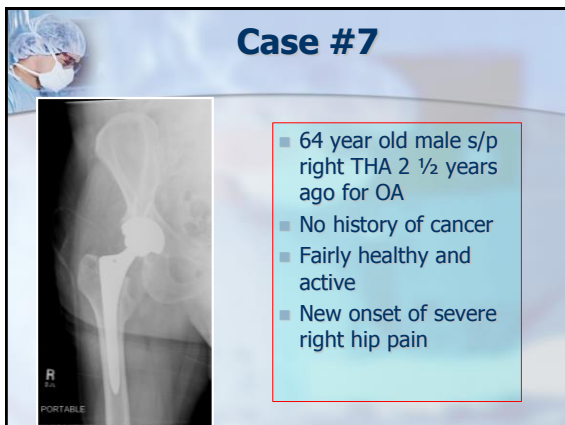
---

---

---

---

---



---

---

---

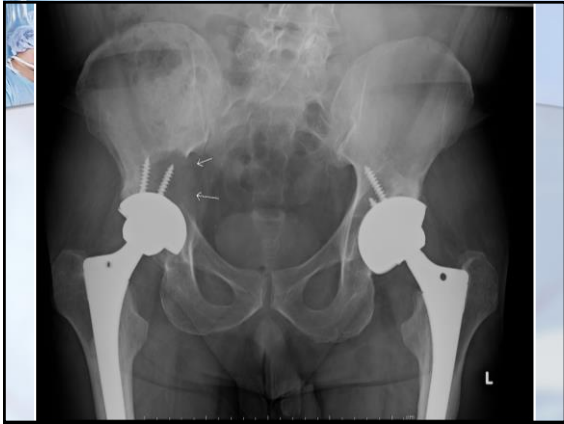
---

---

---

---

---



---

---

---

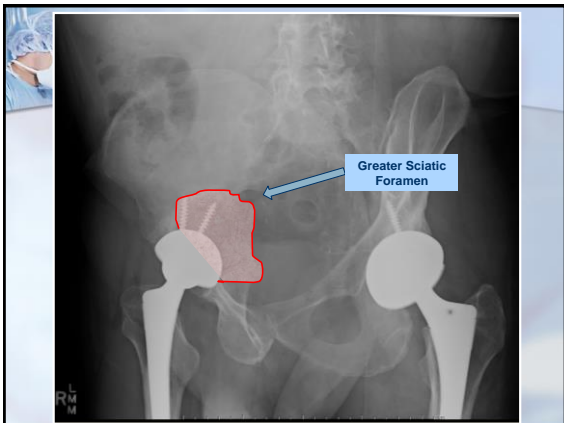
---

---

---

---

---



---

---

---

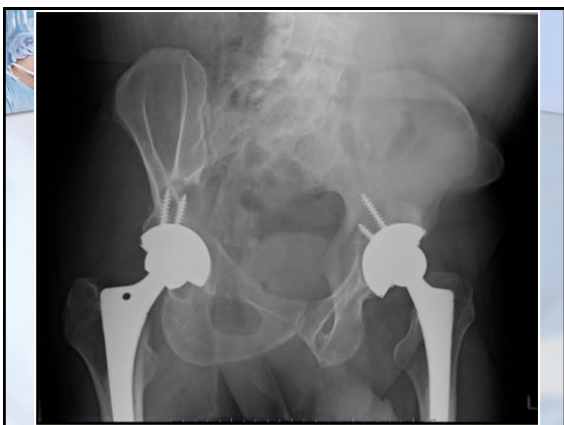---

---

---

---

---



---

---

---

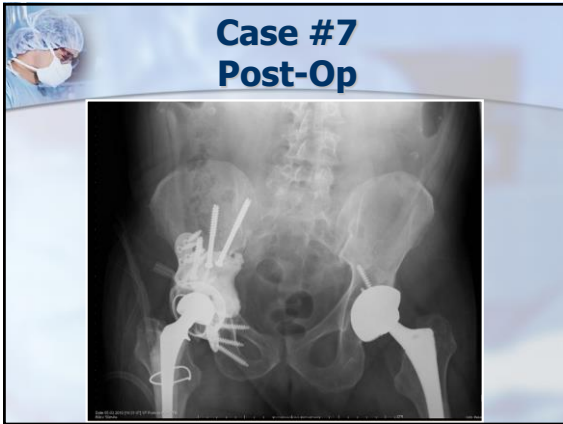
---

---

---

---

---



---

---

---

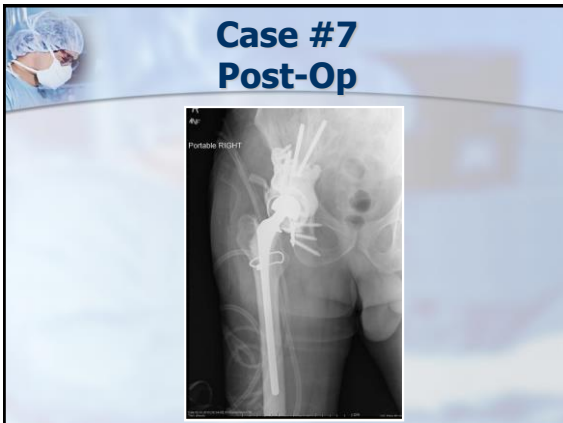---

---

---

---

---



---

---

---

---

---

---

---

---

**Musculoskeletal Oncology**

- **Initial evaluation:**
  - Comprehensive H&P
  - Mass
  - Pain
  - Fever
  - Systemic symptoms: weight loss, appetite decreased, N/V/D, etc.
  - Incidental finding – traumatic event
    - Pathologic fracture

Trinity Health  
of New England

---

---

---

---

---

---

---

---



## Musculoskeletal Oncology

- **Radiologic Work-up:**
  - Plain X-Ray
  - CT scan area of interest
    - CT chest / abdomen / pelvis
  - MRI
  - Bone Scan
  - PET Scan
- **Staging**
- **Pre-operative planning if necessary**

---

---

---


---

---

---

---

---



## Last Words

- Listen to patients
  - History is critical when you can get it
- Recognize "Red Flags"
  - If it doesn't seem normal, it probably isn't
  - Rapid growth, night pain, etc.
  - An injury doesn't mean there can't be another pre-existing or underlying problem
- Staging helps provide diagnostic information and guides treatment
- A biopsy is a critical first step in management with potential implications

---

---

---


---

---

---

---

---



## References

1. Biazzo, A, De Paolis, M. Multidisciplinary approach to osteosarcoma. Acta Orthop Belg. 2016 Dec; 82(4):690-698
2. Zhang, Y, Rosenberg, AE. Bone-Forming Tumors. Surg Pathol Clin. 2017 Sep;10(3):513-535
3. Huang, AJ. Radiofrequency ablation of Osteoid Osteoma: Difficult-to-reach places. Semin Musculoskelet Radiol. 2016 Nov;20(5):486-495
4. Terpos, E, et al. Pathogenesis of bone disease in multiple myeloma: from bench to bedside. Blood Cancer J. 2018 Jan;8(1):7
5. Brown, TS, et al. Reconstruction of the hip after resection of periacetabular oncological lesions: a systematic review. Bone Joint J. 2018 Jan;100-B(1 Supple A):22-30

---

---

---

---

---

---

---

---





---

---

---

---

---

---

---

---